



**PATIENT**

Twin Kliff

**SPECIES**

Feline

**BREED**

DSH

**SEX**

Male Neutered

**AGE**

10 years

**WEIGHT**

13.8lbs

**INTERPRETED BY**

Maggie Machen Lamy,  
DVM, DACVIM  
(Cardiology)

**IMAGING PERFORMED BY**

Kim Liedberg

**HOSPITAL NAME**

SVS Imaging WI

**REFERRING VET**

Dr. Haynes

**INVOICE**

26494

**DATE**

9/21/22

**PRESENTING CLINICAL SIGNS**

History: Grade 2/6 left sided PMI heart murmur was noted on exam 1 month ago. ProBNP was slightly elevated. Please advise medication and anesthesia recommendations.  
-Abnormal PE/Chem/CBC/UA Results: ProBNP: 111 CBC/Chem WNL.

**RADIOGRAPHIC FINDINGS** \*NOTE: Images submitted for supplemental cardiac information only.  
Mild cardiomegaly. No obvious evidence of CHF.

**ECHOCARDIOGRAM FINDINGS**

2D, m-mode, color flow and doppler imaging is available. The left ventricular wall is moderately hypertrophied with regions of irregularity. There is a diffusely hyperechoic endocardium consistent with fibrosis and ventricular remodeling. Mild papillary muscle remodeling. The right ventricle is subjectively normal in size and morphology. There is no left atrial enlargement present. No right atrial enlargement present. Normal RVOT and LVOT velocity. Mild systolic anterior motion (SAM) is suspect on 2D and color flow imaging (not captured on Spectral doppler). There is trace eccentric mitral regurgitation present secondary to SAM. No other significant valvular regurgitation is present. There is no pericardial effusion noted. No pleural effusion appreciated. No obvious cardiac tumors.

**CARDIAC CHART**

FELINE CARDIAC PARAMETERS	BODY WEIGHT (kg)	HR (BPM)	IVSd (cm) <small>(Moise, Pipers)</small>	LVIDd (cm) <small>(Moise, Pipers)</small>	LVWd (cm) <small>(Moise, Pipers)</small>	FS (%)	EF (%)
NORMAL PARAMETER	-----	150-240	0.35-0.55	<2 (mean 1.5)	3.5-0.55	35-67	80-100
PATIENT	6.3	200	0.74	1.26	0.73	58	90
FELINE CARDIAC PARAMETERS	LA/AO <small>(Boon)</small>	LA/AO HEART BASE (Swe) <small>(Abbott)</small>	LA 2D short axis Base view (cm) <small>(Abbott)</small>		LVOT VEL <small>(m/s)</small>	RVOT VEL <small>(m/s)</small>	E max <small>(m/s)</small>
NORMAL	<1.5	<1.3	<1.2		<1.6	<1.3	<0.9
PATIENT	1.3	1.3	1.2		1.7	1.3	NM
<p><i>*Note: All measurements based upon multi-modal images and methods. An average value is reported.</i> Adapted from June Boon, Veterinary Echocardiography, 1998 Abbott J &amp; MacLean H JVIM 2006;20: 111-119, Moise et al. Am J Vet Res 47:1476, 1986. Pipers et al. Am J Vet Res 40:882, 1979.</p>							

**INTERPRETATION OF THE FINDINGS & FURTHER RECOMMENDATIONS**

The diagnosis is hypertrophic obstructive cardiomyopathy (HOCM). This indicates LV thickening (moderate in this case) with a dynamic LVOT obstruction (SAM) and secondary mitral regurgitation as the cause of the heart murmur. The hypertrophy and obstruction are both mild. There is no left atrial enlargement present, indicating the risk of spontaneous CHF and/or a thrombotic event is currently low. No additional issues are identified.

While no medications have been shown to definitively alter long term outcome at this stage of disease, atenolol is often initiated to decrease the outflow obstruction. If the patient is easily medicated, it is reasonable to initiate at this time as below. If there is difficulty medicating at home, an alternative approach would be closely monitoring for progression in the next 6-12

**IMAGING PERFORMED BY**

svsmobileimaging.com 309 - 737 - 3070



**Clinical Sonography & Telecytology**

EDUCATIONAL TELECONSULTATION SERVICES™

1-800-838-4268 info@sonopath.com SonoPath.com

**PATIENT**

Twin Kliff

months. Discussion with the owner is advised. No additional medications are indicated prior to significant atrial dilation.

**SPECIES**

Feline

Monitor at home for any respiratory signs or blood clot events (neurologic change, paralysis, etc.). Anesthetic risk is considered mild, however judicious IV fluid rates are advised to avoid fluid overload. Additionally, drugs that stimulate heart rate should be avoided unless clinically necessary (ketamine, glycopyrrolate, atropine).

**BREED**

DSH

**PLAN**

If elected, administer titrating dose of atenolol: 25mg tablets; Give ¼ tab once daily. Recheck heart rate in 1-2 weeks with target stressed rate of 140-160bpm 12-24 hours post-administration. Increase as needed until target reached.

Screening blood pressure and T4 are recommended every 6 months.

**SEX**

Male Neutered

Recommend recheck echocardiogram in 6 months to assess for progression, sooner if clinical issues arise.

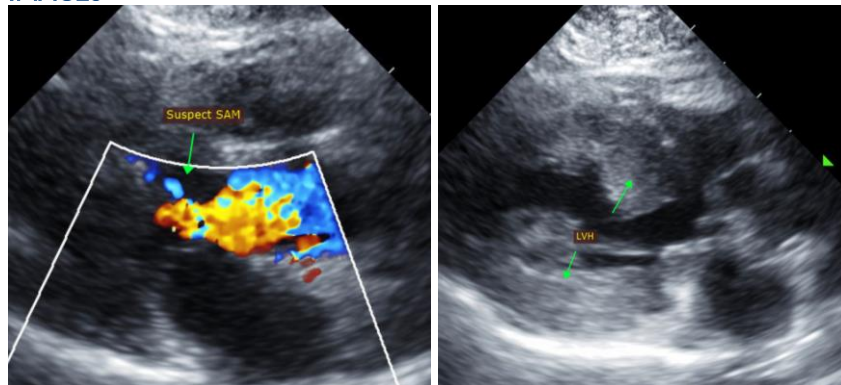
**AGE**

10 years

**IMAGES**

**WEIGHT**

13.8lbs



**INTERPRETED BY**

Maggie Machen Lamy, DVM, DACVIM (Cardiology)

The information and recommendations provided are based on the images presented by the referring veterinarian. No evaluation can be communicated regarding pathology that was not visible in the image/video clips provided.

**IMAGING PERFORMED BY**

Kim Liedberg

Thank you for this referral. If the clinical or image interpretation does not parallel your findings or if I can be of any further assistance, please contact me.

**HOSPITAL NAME**

SVS Imaging WI

Maggie Machen Lamy, DVM  
Diplomate of the American College of Veterinary Internal Medicine (Cardiology)  
info@sonopath.com

**REFERRING VET**

Dr. Haynes

**INVOICE**

26494

**DATE**

9/21/22